

## INCIDENCE AND CASE SERIES OF RARE UNUSAL ECTOPIC PREGNANCY-CAESAREAN SCAR PREGNANCY STUDY IN TERTIARY CARE CENTRE - SIVAGANGAI.

M. Vijayalakshmi<sup>1</sup>, A. Sakthipriya<sup>1</sup>, S. Agnes Synthiah<sup>1</sup>, D. Joycerani<sup>1</sup>

<sup>1</sup>Senior Assistant Professor, Department of Obstetrics and Gynaecology, Government Sivagangai Medical College and Hospital, Tamil Nadu, India.

Received : 24/10/2023  
Received in revised form : 22/11/2023  
Accepted : 05/12/2023

**Keywords:**

Caesarean scar ectopic pregnancy,  
Previous LSCS, Beta HCG, Ectopic pregnancy.

Corresponding Author:

**Dr. S. Agnes Synthiah**

Email: agnessynthiah1111@gmail.com

DOI: 10.47009/jamp.2023.5.6.122

Source of Support: Nil

Conflict of Interest: None declared

*Int J Acad Med Pharm*  
2023; 5 (6); 595-598



### Abstract

**Background:** Caesarean scar ectopic pregnancies are rare form of extrauterine pregnancy. Now a days, its incidence is in increasing trend, in view of increasing in caesarean birth. When compared with other ectopic pregnancy, caesarean scar ectopic pregnancy poses major risk to maternal health and thus maternal mortality can occur. Hence early diagnosis and appropriate management is mandatory. Due to rare incidence and low frequency of this entity, there are no absolute protocols are given for its diagnosis and management. This is the reason which made us to publish this article of case series of this event. **Materials and Methods:** The purpose of this case series is to highlight the various clinical presentation, diagnosis and different modalities of management of caesarean scar pregnancy. **Methods:** This prospective study was done in tertiary care centre, Government Sivagangai Medical College and Hospital, Sivagangai, Tamilnadu, for the period of 3 years from January 2020 to December 2022. A total of 5 cases were studied prospectively. In the period of 3 years, about 116 cases of ectopic pregnancy presented in our department, out of that, 5 cases were caesarean scar pregnancy. In our institution, Incidence of Caesarean scar pregnancy rate was 4.3%. In each case diagnostic ultrasound and Beta HCG measurement was done. Treatment modality was based on hemodynamic condition of the patients. Surgical and medical management were done based on their presentation. **Result:** Out of 5 patients, 4 patients had history of one caesarean, 1 patient had 2 previous caesarean. Out of 5 patients, 1 patient was managed medically, patient was managed by ultrasound guided MVA, 3 patients were managed surgically. **Conclusion:** Caesarean scar ectopic pregnancy is a rare yet life-threatening obstetric condition. It can be diagnosed early with the help of ultrasonography. The treatment is not well defined, yet we consider medical management as the first line of treatment modality in hemodynamically stable patients. Invasive procedures like laparotomy or laparoscopy is reserved for the acute excessive bleeding at the time of presentation. Hence well-defined diagnostic criteria along with algorithmic structured management and follow-up protocol can help in treating this challenging form of rare presentation of ectopic pregnancy.

## INTRODUCTION

Caesarean scar ectopic pregnancy is one of the complication in which an early pregnancy implants in the scar of a previous caesarean delivery.<sup>[1]</sup> Because of worldwide increase in caesarean delivery rates, there seems to be increased incidence of this condition for the past 1 decade. Awareness about the presentation and its management should be created among all obstetricians. Caesarean scar ectopic pregnancy was first described in 1978 by Larsen and Solomon.<sup>[2]</sup> In Caesarean scar pregnancy, the gestation sac will be surrounded by myometrium and

also the fibrous tissue of the scar.<sup>[3]</sup> The mechanism of the scar implantation is related to the invasion of the myometrium through a microscopic tract between the caesarean section scar and the endometrium.<sup>[4]</sup> The clinical presentation is variable. Most of the patients are asymptomatic. It is diagnosed majority by routine ultrasonography. The most probable mechanism which explains scar implantation is that there is invasion of the myometrium through a microtubular tract between the caesarean section scar and the endometrial canal due to damage to the decidua basalis during caesarean or any surgical procedure in uterus can persist in the endometrium in

the form of tiny dehiscence tract or minute defects.<sup>[5]</sup> Undiagnosed CSEP may result to uterine rupture, haemorrhage, and also maternal death. In this review, our main objective is to present a series of clinical cases in which the early and adequate diagnosis made it possible to individualize management and achieve a successful treatment and outcome.

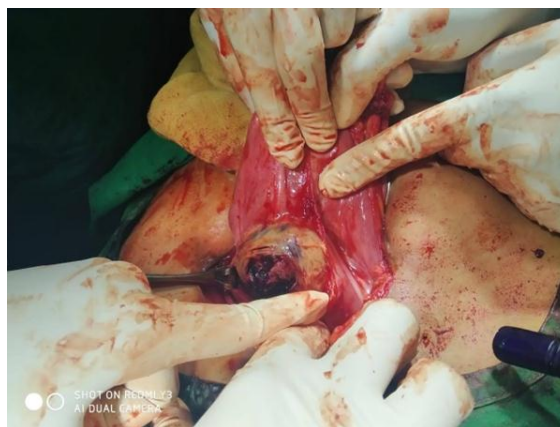## MATERIALS AND METHODS

This study was done in the department of Obstetrics & Gynaecology of Government Sivagangai Medical College and Hospital, Sivagangai, Tamilnadu, India, for a total of three years. Out of 116 ectopic pregnancies, 5 cases were Caesarean scar ectopic pregnancy in 3 years. The incidence of caesarean scar ectopic pregnancy was 4.3%. The patients were diagnosed with caesarean scar pregnancy based on the transvaginal ultrasound scan or MRI pelvis. We analysed the information from the inpatient records from MRD related to presenting complaints, maternal age, gravidity, gestational age, number of previous caesarean section, previous history of abortion, presenting complaints, presence of foetal cardiac activity in an ultrasound scan, history of medical termination of pregnancy (MTP) intake and history of dilatation and curettage in the current pregnancy. The diagnostic ultrasonogram and human chorionic gonadotropin ( $\beta$ -HCG) assay were done in each case.

### CASE REPORTS

#### Case 1

A 35 year old woman G3P2L2 LCB 3 yrs, previous 2 LSCS came to casualty with complaints of 53 days amenorrhoea with severe lower abdominal pain for 1 day, vomiting, with H/O irregular menstrual cycle for past one year, On admission, PR 100/min, BP 110/80 mmHg, urine Pregnancy card test positive, Emergency USG was done which shows mass of size 4\*3 cm noted over lower end of the uterus, uterine cavity empty, no evidence of any adnexal mass, Beta HCG was found to be 4542. In view of persistent tachycardia and severe lower abdominal pain, emergency laparotomy was done, findings are size 4\*4 cm mass (picture 1) was noted over the previous scar and same removed and found to be altered blood clots with few decidual tissues, sent to HPE examination. Then deficient scar was reinforced and suture with 1-0 vicryl and haemostasis secured. Then postoperatively Beta HCG done and found to be decreased to significant level. Patient was discharged after suture removal without any morbidity.

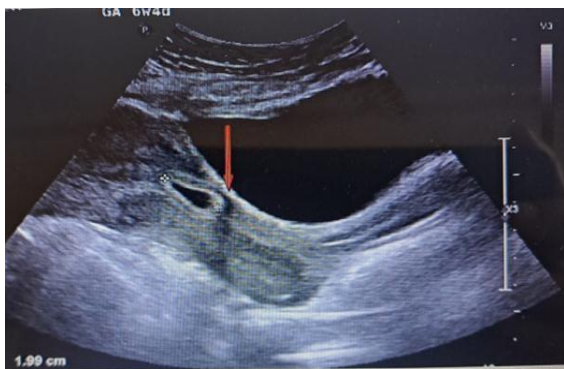


#### Case 2

A 28 years old female patient G3P1L1A1, Previous 1 LSCS, last child birth 3 ½ years, with 5 weeks 6 days Gestation age, came with complaints of bleeding per vagina and abdominal pain for 2 days. USG done which showed Single live Gestational sac in the lower uterine segment adjacent to the scar site, scar thickness 2mm, sac of size 5 weeks 3 days, CRL 6 weeks, with good cardiac activity. Admission vitals were stable. Hence MRI done which showed cystic signal intensity lesion measuring 12\*8 mm at anterior isthmus, No intrauterine gestational sac confirming Endogenous Caesarean Scar Ectopic Pregnancy. Serum Beta HCG assay done and found to be 51019 mIU/ml. Hence Medical treatment combined with Surgical Sac Aspiration was done. Inj Methotrexate 50 mg IM stat dose given, then Ultrasound guided sac aspiration was done. Patient was stable post procedure and discharged. Beta HCG was repeated after 48 hours and found to be 6214 mIU/ml.

#### Case 3

A 33 years old female patient G3P2L2, Previous 1 LSCS last child birth 5 years, with irregular cycle, with H/O 47 days amenorrhoea, referred from PHC with Ultrasound findings of Caesarean scar ectopic pregnancy with Gestational age 6 weeks with yolk sac alone seen in the lower uterine segment with scar thickness 2.5mm. [Picture 2]. Patient did not have any complaints other than amenorrhoea. Beta HCG assay was done and found to be 5023 mIU/ml. Admission vitals was normal, hence planned for medical management. Inj Methotrexate 50 mg IM stat dose was given and patient was monitored. Beta HCG assay monitoring done and patient was discharged in stable condition without any morbidity.



#### Case 4

A 29 years old patient G4P1L1A2 last child birth 5 years, with H/O 49 days amenorrhea followed by excessive bleeding per vagina ,emergency ultrasonogram showed gestational sac with fetus without cardiac activity of gestational age of 6 weeks 2 days in lower uterine segment, admission vitals are PR 106/min, BP 100/60 mmhg, hence under anaesthesia, MVA done under USG guidance, followed which excessive bleeding per vagina noted. On table ultrasonogram showed hemoperitoneum and hence proceeded to Lapaorotomy. Intraoperative findings were, scar rupture noted and products of conception was adherent with the scar and same excised. Then scar is reconstructed and haemostasis secured. One unit of packed cell transfusion done. Patient was discharged without any morbidity.

#### Case 5

A 31 years old patient G2P1L1 last child birth 3 years Previous 1 LSCS, came to our casualty with H/O severe abdominal pain for past 6 hours, with H/O 51 days amenorrhea, Admission vitals was PR 110/min, BP 90/60 mmHg. Urine Pregnancy test was done and found to be positive. Emergency Ultrasonogram showed echogenic mass of size 4\*3 cm, sac like structure seen within the mass in the anterior part of lower uterine segment, absence of myometrium between the bladder wall and the gestational sac. As it is exogenic Caesarean scar ectopic pregnancy and was in impending rupture stage, immediate emergency laparotomy was done. Intraoperative findings were, mass of size 5\*4 cm mass noted over previous scar site and same excised and sent for HPE. Reconstruction of scar was done, complete haemostasis secured. Patient was discharged without any morbidity.

## DISCUSSION

Caesarean Scar Ectopic Pregnancy is a life-threatening condition and it carries a high risk of rupture of uterus and massive haemorrhage. Despite the medical description of caesarean Scar pregnancy was as early as 1978, its diagnosis and management remained unclear. This is due to the rare prevalence of the scar pregnancy. In our study, we found that the symptoms of caesarean scar ectopic pregnancy are

like that of abortion,<sup>[6]</sup> same as compared to the chopra et al study.

The age group range in our case series was 27 to 35 years which was also same when compared to study Maymon et al.<sup>[7]</sup> In our case series,presentation of gestational age was 6 to 8 weeks as compared to the study of Seow et al.<sup>[8]</sup>

Ultrasonography is considered as the first line of diagnostic modality for diagnosing Caesarean scar pregnancy. The four diagnostic features seen in the transvaginal ultrasound are empty uterus, an empty cervical canal, discontinuity in the anterior uterine wall, and the gestational sac located in the anterior part of the isthmic portion of the uterus with a diminished myometrial layer between the bladder and the sac.<sup>[9]</sup> The sensitivity of transvaginal ultrasonography in diagnosing Caesarean scar pregnancy is 86.4%.<sup>[10]</sup> A thin myometrial layer seen adjacent to the bladder wall in the ultrasound. MRI being used as an adjunct to ultrasound imaging for the diagnosis of Caesarean Scar Ectopic Pregnancy, although its incremental benefit over ultrasound imaging alone is unknown.

Treatment is based on the clinical presentation of the patient at the time of admission. If the patient presents with hemodynamically unstable, then emergency laparotomy to be done, either scar excision or hysterectomy may be needed. In our case series,60% patients (3 cases) needed laparotomy and proceeded with scar ectopic resection. Because of the effective and meticulous surgical management, all 3 patients uterus was preserved, hence morbidity reduced. The main advantage of laparotomy or surgical management is quick normalization of  $\beta$ -HCG values and decreases the risk of recurrence as it involves complete removal of the microtubular tract. The medical treatment is done in hemodynamically stable patients. The main advantage of medical management is avoidance of surgery and preservation of fertility. But it is highly crucial to monitor through Beta HCG assay for assessing the response. The medical management includes usage of methotrexate either locally or systemically. A lower  $\beta$ -HCG value and greater than 2 mm myometrial thickness between the gestation sac and the bladder increases the success of methotrexate.<sup>[11]</sup> But, we did not determine any threshold of  $\beta$ -HCG while formulating the management. The success of the medical management is monitored by serial  $\beta$ -HCG assay and is recommended until the value reaches < 5 mIU/ml.<sup>[12]</sup>

We observed that systemic methotrexate is more effective primary modality in the mangement of Caesarean Scar Pregnancy with minimal complications. However, this is acceptable only in the absence of fetal cardiac activity. The most possible explanation could be slow absorption or activity of the drug which may fail to inhibit the vascularisation of the growing fetus resulting in secondary bleeding.

The higher value of  $\beta$ -HCG levels are found in most cases of cesarean scar pregnancy as it can be

presented even in late first trimester and this should not be considered as an inhibition to resort to the non-surgical methods especially in women who desires for future fertility. The women should be counseled about the likely success of the procedure, outcome of the management, the possibility of acute hemorrhage during the follow-up, and the slow resolution of the visible scar pregnancy on the ultrasound. Ultrasound guided aspiration or hysteroscopic guided aspiration can also be done, if needed diagnostic laparoscopy with hysteroscopy can be done. In our series, we managed ultrasound guided aspiration along with systemic methotrexate, as beta HCG was in higher level.

## CONCLUSION

Caesarean scar ectopic pregnancy is a rare yet life-threatening dreadly obstetric condition. It can be diagnosed early with the help of ultrasonography. The treatment is not well defined, yet we consider medical management as the first line of treatment modality in hemodynamically stable patients. Invasive procedures like laparotomy or laparoscopy is reserved for the acute excessive bleeding at the time of presentation.  $\beta$ -HCG assay should not be the determining factor for management of this rare presentation of ectopic pregnancy. A screening tool for evaluating at-risk patients and protocol for escalating to MRI for equivocal cases should be available at the point of care. Hence well-defined diagnostic criteria along with algorithmic structured management and follow-up protocol can help in treating this challenging form of rare presentation of ectopic pregnancy.

## REFERENCES

1. Riaz RM, Williams TR, Craig BM, Myers DT. Caesarean scar ectopic pregnancy: imaging features, current treatment options, and clinical outcomes. *Abdom Imaging* 2015;40:2589–99.
2. Larsen JV, Solomon MH: Pregnancy in a uterine scar sacculus--an unusual cause of postabortal haemorrhage. A case report. *S Afr Med J*. 1978, 53:142-143.
3. Coniglio C, Dickinson JE: Pregnancy following prior caesarean scar pregnancy rupture: lessons for modern obstetric practice. *Aust N Z J Obstet Gynaecol*. 2004, 44:162-165.
4. Fylstra DL: Ectopic pregnancy within a cesarean scar: a review . *Obstet Gynecol Surv*. 2002, 57:537-543.
5. Rotas, M.A.; Haberman, S.; Levgur, M. Caesarean scar ectopic pregnancies etiology. *Am. Coll. Obstet. Gynecol*. 2006, 107, 1373–1381. [CrossRef] [PubMed]
6. Agarwal N, Gainder S, Chopra S, et al. (June 23, 2021) The Management of Scar Ectopic: A Single-Center Experience. *Cureus* 13(6): e15881. DOI 10.7759/cureus.15881
7. Maymon R, Halperin R, Mendlovic S, Schneider D, Vaknin Z, Herman A, Pansky M: Ectopic pregnancies in caesarean section scars: the 8 year experience of one medical centre. *Hum Reprod*. 2004, 19:278-284. 10.1093/humrep/deh060
8. Seow KM, Hwang JL, Tsai YL: Ultrasound diagnosis of a pregnancy in a Cesarean section scar . *Ultrasound Obstet Gynecol*. 2001, 18:547-549. 10.1046/j.0960-7692.2001.00569.x
9. Godin PA, Bassil S, Donnez J: An ectopic pregnancy developing in a previous caesarean section scar . *Fertil Steril*. 1997, 67:398-400. 10.1016/S0015-0282(97)81930-9
10. Lai YM, Lee JD, Lee CL, Chen TC, Soong YK: An ectopic pregnancy embedded in the myometrium of a previous cesarean section scar. *Acta Obstet Gynecol Scand*. 1995, 74:573-576. 10.3109/00016349509024394
11. Glenn TL, Bembry J, Findley AD, Yaklic JL, Bhagavath B, Gagneux P, Lindheim SR: Cesarean scar ectopic pregnancy: current management strategies. *Obstet Gynecol Surv*. 2018, 73:293-302.10.1097/OGX.0000000000000561.
12. Lai YM, Lee JD, Lee CL, Chen TC, Soong YK: An ectopic pregnancy embedded in the myometrium of a previous cesarean section scar. *Acta Obstet Gynecol Scand*. 1995, 74:573-576. 10.3109/00016349509024394